

# Novi slučaj prolazne hiperfosfatazemije u 21-mjesečnog djeteta s ponavljajućom sipnjom - prikaz bolesnika

---

Zrinski-Topić, Renata; Raos, Miljenko; Demirović, Jadranka; Živčić, Jadranka; Čepelak, Ivana; Petrinović, Rajka; Dodig, Slavica

Source / Izvornik: **Biochemia Medica**, 2008, 18, 224 - 229

Journal article, Published version

Rad u časopisu, Objavljena verzija rada (izdavačev PDF)

Permanent link / Trajna poveznica: <https://urn.nsk.hr/urn:nbn:hr:163:542992>

Rights / Prava: [In copyright](#) / [Zaštićeno autorskim pravom](#).

Download date / Datum preuzimanja: **2025-02-27**



Repository / Repozitorij:

[Repository of Faculty of Pharmacy and Biochemistry University of Zagreb](#)



## Novi slučaj prolazne hiperfosfatazemije u 21-mjesečnog djeteta s ponavljajućom sipnjom – prikaz bolesnika

### A new case of transient hyperphosphatasemia in a 21-month-old child with recurrent wheezing – case report

Renata Zrinski-Topić<sup>1</sup>, Miljenko Raos<sup>2</sup>, Jadranka Demirović<sup>3</sup>, Jadranka Živčić<sup>1</sup>, Ivana Čepelak<sup>4</sup>, Rajka Petrinović<sup>3</sup>, Slavica Dodig<sup>1</sup>

<sup>1</sup>Odjel za kliničko-laboratorijsku dijagnostiku, Dječja bolnica „Srebrnjak“, Referentni centar Ministarstva zdravstva za kliničku alergologiju djece, Zagreb

<sup>1</sup>Department of Clinical Laboratory Diagnosis, Srebrnjak Children's Hospital, Reference Center for Clinical Allergology in Children of the Ministry of Health, Zagreb, Croatia

<sup>2</sup>Odjel za pulmologiju i alergologiju dojenčadi i male djece, Dječja bolnica „Srebrnjak“, Referentni centar Ministarstva zdravstva za kliničku alergologiju djece, Zagreb

<sup>2</sup>Department of Pulmonology and Allergology in Infants and Small Children, Srebrnjak Children's Hospital, Reference Center for Clinical Allergology in Children of the Ministry of Health, Zagreb, Croatia

<sup>3</sup>Medicinsko-biokemijski laboratorij, Klinika za tumore, Zagreb

<sup>3</sup>Laboratory of Medical Biochemistry, University Hospital for Tumors, Zagreb, Croatia

<sup>4</sup>Zavod za medicinsku biokemiju i hematologiju, Farmaceutsko-biokemijski fakultet Sveučilišta u Zagrebu, Zagreb

<sup>4</sup>Department of Medical Biochemistry and Hematology, School of Pharmacy and Biochemistry, University of Zagreb, Zagreb, Croatia

#### Sažetak

**Uvod:** Opisuje se slučaj prolazne hiperfosfatazemije u 21-mjesečnog dječaka s ponavljajućom sipnjom tijekom akutnog respiracijskog infekta.

**Materijali i metode:** Određivanje katalitičke aktivnosti alkalne fosfataze provedeno je preporučenom fotometrijskom metodom, a elektroforetsko razdvajanje izoenzima alkalne fosfataze na agaroznom gelu uz obradu seruma lektinom.

**Rezultati:** Tijekom bolničkog liječenja djeteta je imalo povećanu katalitičku aktivnost alkalne fosfataze: prvog dana 4109 U/L, šestog dana 2156 U/L. Pri kontrolnom pregledu 27. dana od prijama u bolnicu aktivnost se smanjila na 505 U/L. Elektroforetskim razdvajanjem izoenzima alkalne fosfataze dokazana je elektroforetska vrpca brža od jetreno-koštanog izoenzima, tzv. brza anodna vrpca.

**Zaključak:** Pojava izrazito povećane katalitičke aktivnosti alkalne fosfataze uz tipičnu elektroforetsku razdiobu izoenzima u trajanju od nekoliko tjedana ukazuje na prolaznu hiperfosfatazemiju. Pravodobnim prepoznavanjem izbjegava se daljnja nepotrebna dijagnostička obrada.

**Ključne riječi:** prolazna hiperfosfatazemija, alkalna fosfataza, izoenzimi, sipnja, djeteta

#### Abstract

**Introduction:** A case of transient hyperphosphatasemia in a 21-month-old boy diagnosed with recurrent wheezing during acute respiratory infection is described.

**Materials and methods:** Determination of alkaline phosphatase catalytic activity was performed by the recommended photometric method, and electrophoretic separation of alkaline phosphatase isoenzymes on agarose gel by serum processing with lectin.

**Results:** During hospital treatment, increased catalytic activity of alkaline phosphatase was recorded (4109 U/L on day 1 and 2156 U/L on day 6). On control examination on day 27 of hospital admission, the value decreased to 505 U/L. Electrophoretic separation of alkaline phosphatase isoenzymes demonstrated a band faster than the hepatic-osseous isoenzyme, a fast anodal form.

**Conclusion:** A marked increase in the alkaline phosphatase catalytic activity with typical electrophoretic isoenzyme pattern persisting for several weeks points to transient hyperphosphatasemia. Additional unnecessary diagnostic work-up can be obviated by timely recognition of the phenomenon.

**Keywords:** hyperphosphatasemia, alkaline phosphatase, isoenzymes, wheezing, infant

Pristiglo: 10. rujna 2007.

Prihvaćeno: 15. siječnja 2008.

Received: September 10, 2007

Accepted: January 15, 2008

## Uvod

Alkalna fosfataza, ortofosfat-monoester-fosfohidrolaza (ALP; EC 3.1.3.1) je skupina hidrolaza s optimumom aktivnosti u alkalnom području (pH 9,8 do 10,5). Razlikuju se tkivno nespecifični izoenzim (jetreno-koštano-bubrežni), crijevni, placentni i izoenzim sličan placentnom koji nalazimo u testisima, timusu i plućima. Atipični ili višestruki oblici alkalne fosfataze su negenskog podrijetla i pojavljuju se u pojedinim patološkim stanjima (1,2). Katalitička aktivnost alkalne fosfataze je zbog koštanog rasta u dječjoj dobi i u pubertetu veća nego u odrasle osobe. U serumu dojenčadi i djece moguća je izrazito povećana aktivnost, i do 20 puta od gornje granice referentnih vrijednosti za određenu dob, ali bez prisutnosti jetrenih ili koštanih bolesti (2,3). Prolazna hiperfosfatazemija dojenčadi i djece (engl. *transient hyperphosphatasemia*, TH) ili benigna prolazna hiperfosfatazemija (engl. *benign transient hyperphosphatasemia*, BTH) je prvi put opisana 1954. godine (3), a u Hrvatskoj 1986. godine (4). Budući da u djece nema kliničkih znakova metabolične koštane ili jetrene bolesti, otkriva se slučajno tijekom laboratorijske obrade bolesnog djeteta.

Cilj rada bio je prikazati slučaj i podsjetiti na prolaznu hiperfosfatazemiju kao benignu pojavu, kako bi se izbjegla daljnja nepotrebna dijagnostička obrada. Prema našem saznanju to je prvi prikaz prolazne hiperfosfatazemije u djeteta s ponavljajućom sipnjom tijekom akutnog respiracijskog infekta.

## Materijali i metode

### Metode

Biokemijske pretrage određivanja aktivnosti enzima i koncentracije metabolita provedene su na analizatoru Olympus AU400 (Olympus Optical Co., Ltd., Tokyo, Japan) s izvornim komercijalnim reagensijama (Olympus Diagnostic, GmbH, Hamburg, Njemačka). Katalitička aktivnost alkalne fosfataze određena je preporučenom fotometrijskom, kontinuiranom metodom (p-nitrofenilfosfat, AMP pufer, Mg-acetat, Zn-sulfat, HEDTA) (5).

Elektroforetsko razdvajanje izoenzima alkalne fosfataze učinjeno je na agaroznom gelu (Hydragel 7/15 ISO-PAL gelovi, Sebia Products, Issy-les-Moulineaux, Francuska) uz automatski elektroforetski sustav Hydrasis, denzitometar Hydrasys 2 (Sebia system, EVRY Cedex, Francuska) uz prethodnu obradu seruma lektinom (6). Prije nanošenja na agarozu serumi su razrijeđeni do približno jednakih vrijednosti katalitičke aktivnosti ALP.

### Prikaz bolesnika

Dječak u dobi od 21 mjeseca zaprimljen je na Odjel za pulmologiju i alergologiju dojenčadi i male djece zbog liječenja akutnoga respiracijskog infekta s ponavljajućom

## Introduction

Alkaline phosphatase, orthophosphate-monoester-phosphohydrolase (ALP; EC 3.1.3.1) is a group of hydrolases with optimal activity in alkaline range (pH 9.8-10.5). ALP includes tissue nonspecific isoenzyme (liver-bone-kidney), intestinal, placental and placental-like isoenzyme which is expressed in the testes, thymus and lungs. Atypical or multiple forms of ALP are of non-gene origin and occur in particular pathologic states (1,2). Because of bone growth, the catalytic activity of ALP is greater in childhood and puberty than in adults. ALP catalytic activity can be extremely increased, up to 20-fold upper reference limit for age, in serum of infants and children, even in the absence of hepatic or bone disease (2,3). Transient hyperphosphatasemia (TH) in infants and children or benign transient hyperphosphatasemia (BTH) was first described in 1954 (3), and in Croatia in 1986 (4). As these children show no clinical signs of metabolic bone or liver disease, TH is incidentally detected on laboratory work-up for some illnesses.

The aim is to present a case of TH and to remind of hyperphosphatasemia as a benign phenomenon where additional diagnostic procedures can be avoided. To the best of our knowledge, this is the first report of TH in a child with recurrent wheezing during acute respiratory infection.

## Materials and methods

### Methods

Biochemical testing, including enzyme activity and concentration metabolite determination, was performed on an Olympus AU 400 analyzer (Olympus Optical Co., Ltd., Tokyo, Japan) with original commercial reagents (Olympus Diagnostic, GmbH, Hamburg, Germany). The catalytic activity of ALP was determined by the recommended photometric continuous method (p-nitrophenylphosphate, AMP buffer, Mg-acetate, Zn-sulfate, HEDTA) (5).

Electrophoretic separation of ALP isoenzymes was done on agarose gel (Hydragel 7/15 ISO-PAL gels, Sebia Products, Issy-les-Moulineaux, France) with the use of the Hydrasis automated electrophoresis system, Hydrasis 2 densitometer (Sebia System, EVRY Cedex, France) with serum lectin pretreatment (6). Prior to application onto the agarose, the sera were diluted to approximately the same value of ALP catalytic activity.

### Case report

A 21-month-old male child was admitted to Department of Pulmonology and Allergology in Infants and Small Children for the management of acute respiratory infection with recurrent wheezing. The child had a 6-month history of frequent respiratory infections with recurrent whee-

sipnjom. Unatrag šest mjeseci dječak je imao česte respiracijske infekcije s ponavljajućom sipnjom, otkrivena je povećana koncentracija ukupnog IgE (IgE 151,8 kIU/L; gornja granica referentnog raspona za dob je 38,6 kIU/L (7)) te je bio ambulantno liječen bronhodilatatorima kratkoga (salbutamol) i dugog djelovanja (flutikazon propionat). Kod prijma dječak je bio afebrilan, blijed, blaže dispnoičan, respiracije 35/min (blaži respiracijski poremećaj). Izdisaj je bio otežan i produljen, obostrano su se čuli hropci. Nalazi srca i abdomena bili su bez osobitosti. RTG snimka pluća je bez patoloških promjena. Dječak je liječen bronhodilatatorima, glukokortikoidima, inhalacijama salbutamola i respiracijskom kineziterapijom. Nakon šest dana dječak je otpušten urednoga kliničkog statusa na kućnu njegu uz preporučenu terapiju inhalacijskim bronhodilatatorom dugog djelovanja. Na kontrolni pregled je došao 27. dana od početka bolesti. Na drugi kontrolni pregled nije došao. Prije hospitalizacije majka je dala obaviješteni pristanak, a dijagnostički postupci provedeni su u skladu s etičkim načelima i Deklaracijom o ljudskim pravima iz Helsinkija 1975. i izmjenama iz Tokija 2004. godine (8).

## Rezultati

Rezultati laboratorijskih nalaza u tijeku bolničkog liječenja te nakon kraćega kućnog liječenja prikazani su u tablici 1. Katalitička aktivnost alkalne fosfataze smanjila se od prvog do šestog dana na 52% početne vrijednosti, a kroz idući 21 dan na 12% početne vrijednosti, odnosno gotovo na gornju granicu referentnog raspona za dob. Elektroforetsko razdvajanje izoenzima ALP prikazano je na slici 1.

**TABLICA 1.** Rezultati laboratorijskih pretraga za vrijeme bolničkog liječenja (1. i 6. dana) i nakon kućnog liječenja (nakon 27. dana).

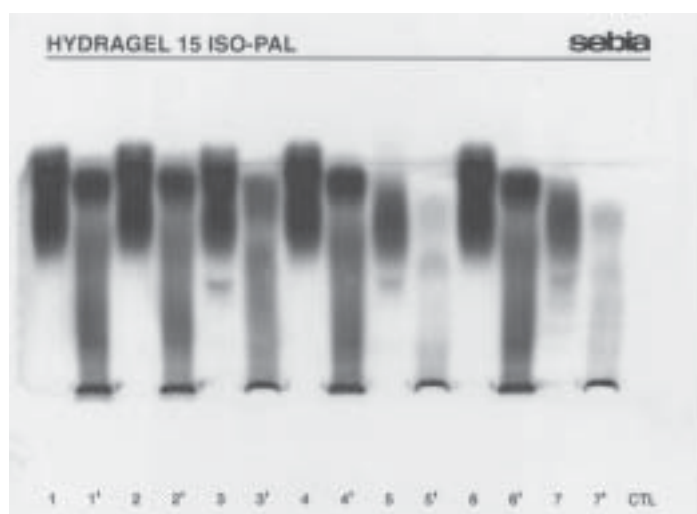
Analysis	Day 1	Day 6	Day 27	Reference range
CRP (mg/L)	11.9	-	-	0.0-10.0
ESR (mm/3.6 ks)	19	-	-	0-20
Leukocytes (x10 <sup>9</sup> /L)	17.5	-	10.4	6.0-16.0
Platelets (x10 <sup>9</sup> /L)	669	-	561	150-450
ALP (U/L)	4109	2156	505	25-500
AST (U/L)	33	22	35	26-75
ALT (U/L)	20	9	15	11-46
GGT (U/L)	12	14	10	1-39
LDH (U/L)	315	217	311	150-360
Total bilirubin (μmol/L)	7.4	-	-	<20
Calcium (mmol/L)	2.56	2.51	2.59	2.15-2.80
Phosphate (mmol/L)	1.81	1.77	1.65	0.95-1.80

zing and a finding of elevated total IgE concentration (IgE 151.8 kIU/L; the upper limit of the reference range for age is 38.6 kIU/L (7)), treated with short-acting (salbutamol) and long-acting (fluticasone propionate) bronchodilators on outpatient basis. On admission, the child was afebrile, pale, mildly dyspneic, respiration rate 35/min (mild respiratory distress); expiration difficult and prolonged, with bilateral rales. The heart and abdomen were normal. Chest x-ray showed no pathologic findings. The patient was treated with bronchodilators, glucocorticoids, salbutamol inhalation and respiratory kinesitherapy. After six days, the patient was discharged with normal clinical status for home care and recommended therapy with a long-acting inhalation bronchodilator. The patient presented for control examination on day 27 of the disease onset, but failed to come for second control. The patient's mother signed the informed consent form prior to hospitalization and diagnostic work-up was performed according to the standardized procedure, in line with ethical principles, Helsinki Declaration on Human Rights from 1975 and Tokyo amendments from 2004 (8).

## Results

Laboratory findings recorded during hospitalization and a short period of home care are presented in Table 1. Catalytic activity of ALP decreased from day 1 to day 6 to 51% and over the next 21 days to 12% of the initial value, i.e. near the upper limit of the reference range for age. Electrophoretic separation of ALP isoenzymes is presented in Figure 1. Native serum samples showed altered

**TABLICA 1.** Results of laboratory analyses during hospital treatment (day 1 and 6) and after home treatment (day 27)



**SLIKA 1.** Elektroforetsko razdvajanje izoenzima ALP na agaroznom gelu prije i poslije obrade lektinom. Izoenzimi ALP u nativnom serumu (linije 1, 2 i 3) i serumu obrađenom lektinom (linije 1', 2' i 3') dječaka s hiperfosfatazemijom 1., 6. i 27. dana liječenja akutnog respiracijskog infekta s ponavljajućom sipnjom. Izoenzimi ALP u nativnom serumu (5 i 7) i serumu obrađenom lektinom (5' i 7') kontrolnih uzoraka.

**FIGURE 1.** Electrophoretic separation of ALP isoenzymes on agarose gel before and after lectin pretreatment. ALP isoenzymes in native serum (samples 1, 2 and 3) and serum after lectin pretreatment (samples 1', 2' and 3') of hyperphosphatasemia patient on day 1, 6 and 27 of therapy for acute respiratory infection with recurrent wheezing. ALP isoenzymes in control native serum (samples 5 and 7) and serum after lectin pretreatment (5' and 7').

Nativni uzorci seruma dječaka s hiperfosfatazemijom pokazuju promijenjenu elektroforetsku pokretljivost izoenzima: brza anodna (brža od jetreno-koštano-placentnog područja) i sporija anodna (putuje u jetreno-koštano-placentnom području) vrpca. Promjena je naročito izražena u uzorcima seruma prvog i šestog dana liječenja (linije 1 i 2). Nakon obrade seruma lektinom još bolje se ističe brzi anodni oblik (linije 1' i 2'). Elektroforetskim razdvajanjem određena katalitička aktivnost brzog oblika je 1422 U/L prvog dana, 802 U/L šestog dana i 76 U/L 27. dana. Kada se katalitička aktivnost ALP smanjila do gornje granice referentnog raspona, elektroforeza izoenzima je poprimila značajke zdravog dječjeg seruma (linije 5 i 7), osobito nakon obrade lektinom (linije 5' i 7'). Razlikuje se još uvijek prisutan, ali slabije izražen brzi anodni oblik difuzno povezan s jetrenim oblikom (linije 3 i 3'). U kontrolnim uzorcima (linija 5) razlikuju se jetreno-koštani i izoenzim sličan placentnom odnosno i crijevni izoenzim (linija 7).

## Rasprava

Kriteriji za postavljanje dijagnoze prolazne hiperfosfatazemije su: dob djeteta manja od 5 godina; različiti simptomi poput respiracijske infekcije, proljeva, povraćanja; izostanka kliničkih i biokemijskih znakova koštane i jetrene bolesti; povećane vrijednosti ALP 3 do 50 puta od gornje granice referentnog raspona vrijednosti za dob; povećane

electrophoretic isoenzyme motility, i.e. rapid anodal (faster than the hepatic-osseous-placental area) and slower anodal (moving in the hepatic-osseous-placental area) bands. The change was especially pronounced in serum samples collected on day 1 and day 6 of treatment (lanes 1 and 2). Upon lectin treatment, the rapid anodal form was even more pronounced, along with separation of the remaining fractions (lanes 1' and 2'). The rapid form catalytic activity determined by electrophoretic separation was 1422 U/L on day 1, 802 U/L on day 6 and 76 U/L on day 27. When the ALP catalytic activity decreased to the upper reference limit, isoenzyme electrophoresis assumed the characteristics of normal pediatric serum (lanes 5 and 7), especially upon treatment with lectin (lanes 5' and 7'). The rapid anodal form diffusely associated with the hepatic form was less pronounced but still present (lanes 3 and 3'). In control samples, the hepatic-osseous and placental-like isoenzymes (lane 5) and intestinal isoenzyme (lane 7) were observed.

## Discussion

The following criteria are used on making the diagnosis of transient hyperphosphatasemia: age below 5 years; various symptoms such as respiratory infections, diarrhea, vomiting; absence of clinical and biochemical signs of liver and bone disease; increased ALP level, 3- to 50-fold

aktivnosti koštanog i/ili jetrenog izoenzima; povratka na normalne vrijednosti unutar 4 mjeseca (3).

Dječak zaprimljen na liječenje zbog akutnog respiracijskog infekta zadovoljavao je pet dijagnostičkih uvjeta: bio je u dobi od 21 mjeseca; imao je respiracijski infekt; klinički nalaz, RTG snimka i laboratorijski nalazi (tablica 1.) nisu ukazivali na bolesti kostiju ili jetre; aktivnost ALP u prvom određivanju bila je osam puta veća od gornje granice referentnog raspona vrijednosti za dječakovu dob; nakon četiri tjedna uslijedilo je smanjenje aktivnosti ALP na 505 U/L, gornja granica referentnog raspona za dob je 500 U/L (5). Etiologija prolazne hiperfosfatazemije nije potpuno razjašnjena. Najčešće se pojavljuje u tijeku infekcija (9), osobito akutnih virusnih infekcija (10-12). U djece s prolaznom hiperfosfatazemijom koja se pojavila tijekom infektivnih bolesti gornjih dišnih putova praćenih vrućicom i proljevom dokazana je i povećana koncentracija antitijela protiv enterovirusa Echo 22, Enterovirus 71 i Coxsackie B4 (11), a opisana je i u slučaju infekcije rotavirusom u djeteta s transplantiranim jetrima (13). Prolazna hiperfosfatazemija dokazana je i u bolesnika s egzantematoznom vrućicom nakon primjene cjepiva protiv ospice (14). Može se pojaviti u 2,8% djece s transplantacijom jetre ili bubrega (15). Veća pojavnost prolazne hiperfosfatazemije zamijećena je u kalendarskom dijelu godine kada su virusne infekcije češće (12,16). Prikazani dječak imao je unatrag šest mjeseci od opisanog prijma učestale respiracijske infekcije, a temeljem prikupljenih nalaza može se zaključiti o virusnoj etiologiji. Pretpostavlja se da različita patološka stanja, među kojima se naročito ističe virusna infekcija, mijenjaju stupanj sialinacije molekule ALP, zbog čega se smanjuje klirens enzima (17). Drugi autori opisuju pojavu atipične ALP s elektroforetskom pokretljivošću u brzom  $\alpha 2$  ili  $\alpha 1/\alpha 2$ -globulinskoj zoni (10,12). Ispitivanja katalitičkih svojstava atipičnog oblika ALP u prolaznoj hiperfosfatazemiji govore u prilog jetrenom obliku s viškom sialinske kiseline, premda nije utvrđena pojačana sialinacija drugih proteina. Obrade sialidazom ili lektinom nisu dovoljno djelotvorne da bi atipičan jetreni oblik ALP prevele u normalan jetreni oblik ALP (10). Elektroforetskim razdvajanjem izoenzima ALP u ispitivanog je dječaka zamijećena jaka vrpca, koju možemo opisati kao atipični izoenzim brži od jetreno-koštanog izoenzima, tzv. brzi anodni. U uzorcima prvog i šestog dana obrađenim lektinom denzitometrijski je određen relativni postotak brzog anodnog oblika u vrijednosti od 35% odnosno 37%. Usporedno sa smanjenjem aktivnosti ukupne ALP, uslijedila je i promjena elektroforetske slike u uzorku 27. dana kada je vrijednost brzog anodnog oblika smanjena na 15%. Nažalost, na drugi kontrolni pregled dječak nije došao pa se nije mogla još jednom odrediti katalitička aktivnost ukupne ALP ni izoenzima ALP, za koje pretpostavljamo da bi se smanjile unutar referentnog intervala, kako je već opisano (18). Dodatno ograničenje bila je mala količina uzorka.

upper limit of the age specific reference range; elevated activity of osseous and/or hepatic isoenzymes; and return to normal levels within 4 months (3).

In the child admitted for acute respiratory infection, five diagnostic criteria were met: age 21 months; presence of respiratory infection; clinical findings, chest x-ray and laboratory findings (Table 1) not indicative of bone or liver disease; on first determination, ALP activity was eight-fold upper limit of the respective age specific reference range; and a decrease in ALP activity to 505 U/L (upper limit of the age specific reference range is 500 U/L) within four weeks (5).

The etiology of transient hyperphosphatasemia has not yet been fully clarified. It most frequently occurs during infections (9), in particular acute viral infections (10-12). Elevated concentration of antibodies to Echo 22, Enterovirus 71 and Coxsackie B4 enteroviruses was demonstrated in children with transient hyperphosphatasemia that developed during the upper airway infections accompanied by fever and diarrhea (12), and has also been described during rotavirus infection in a child with liver transplantation. Transient hyperphosphatasemia was demonstrated in a patient with exanthematous fever following measles vaccination (14), and has been reported to occur in 2.8% of children undergoing liver or kidney transplantation (15). A higher incidence of transient hyperphosphatasemia has been recorded in the seasons characterized by a higher rate of viral infections (12,16).

Prior to admission, our patient had a 6-month history of recurrent respiratory infections, most probably of viral etiology. Various pathologic states such as viral infection have been postulated to modify the rate of ALP molecule sialinization, thus reducing the enzyme clearance (17). Other authors report the appearance of atypical ALP of electrophoretic motility in the rapid  $\alpha 2$  or  $\alpha 1/\alpha 2$ -globulin area (10,12). Studies of the catalytic properties of atypical ALP form in transient hyperphosphatasemia suggest the hepatic form with excess sialic acid, although enhanced sialinization of other proteins has not been detected. Treatment with sialidase or lectin is not efficient enough to translate the atypical hepatic ALP form into normal hepatic ALP form (10). In the study patient, electrophoretic separation of ALP isoenzymes yielded a strong band that could be characterized as an atypical fast anodal form faster than the hepatic-osseous isoenzyme. Relative percentage of the rapid anodal form, determined by densitometry in the lectin processed samples collected on day 1 and day 6 was 35% and 37%, respectively. The decrease in total ALP activity was accompanied by a changed electrophoretic pattern in the sample obtained on day 27, when the percentage of the rapid anodal form decreased to 15%. Unfortunately, the child did not present for the second check-up, so the catalytic activity of ALP and ALP isoenzymes, presumed to have decreased to the referen-

Premda se elektroforeza smatra pouzdanim postupkom za razlikovanje izoenzima ALP, dodatna ispitivanja katalitičkih svojstva ili stabilnosti izoenzima ALP nije bilo moguće provesti.

## Zaključak

U zaključku želimo naglasiti da pri slučajnom nalazu velike katalitičke aktivnosti ALP u rano dječje doba u tijeku akutne respiracijske ili crijevne infekcije treba posumnjati na postojanje prolazne hiperfosfatazemije kako bi se izbjegla daljnja nepotrebna dijagnostička obrada. Ako se vrijednosti normaliziraju unutar četiri mjeseca daljnja ispitivanja nisu potrebna.

## Adresa za dopisivanje:

Renata Zrinski-Topić  
 Odjel za kliničko-laboratorijsku dijagnostiku  
 Dječja bolnica Srebrnjak  
 Srebrnjak 100  
 10000 Zagreb  
 e-pošta: renata.zrinski-topic@zg.t-com.hr  
 tel: 01 6391 153  
 faks: 01 6391 188

ce range as described elsewhere (18), could not be determined again. The inadequate sample volume was an additional limitation of the study. Although serum protein electrophoresis is a reliable method for ALP isoenzyme differentiation, additional studies like catalytic properties or stability of ALP isoenzymes could not be performed.

## Conclusion

In conclusion, transient hyperphosphatasemia should be considered in case of an incidental finding of high catalytic activity of ALP in early childhood during acute respiratory or intestinal infection, thus obviating additional unnecessary diagnostic work-up. If the levels normalize within four months, there is no need for additional testing.

## Corresponding author:

Renata Zrinski-Topić  
 Department of Clinical Laboratory Diagnosis  
 Srebrnjak Children's Hospital  
 Srebrnjak 100  
 10000 Zagreb  
 Croatia  
 e-mail: renata.zrinski-topic@zg.t-com.hr  
 phone: +385 1 6391-153  
 fax: +385 1 6391-188

## Literatura/References

1. Thomas L. Alkaline phosphatase (ALP). In: Thomas L, ed. *Clinical Laboratory Diagnostics*. Frankfurt/Main: TH-Books-Verl.-Ges.;1998. pp. 36-46.
2. Sokolić B, Čepelak I. [Izoenzimi i višestruki oblici alkalne fosfataze; značenje, mogućnosti određivanja]. *Biochemia Medica* 1994;4:113-21. (in Croatian)
3. Kraut JR, Metrick M, Maxwell NR, Kaplan MM. Isoenzyme studies in transient hyperphosphatasemia of infancy. Ten new cases and a review of the literature. *Am J Dis Child* 1985;139:736-40.
4. Jurčić Z, Rudar D, Hajnčić TF, Cvitanović Lj, Babić M. [Benigna tranzitorna hiperfosfatazemija]. *Knjiga sažetaka V. Jugoslavensko-austrijski simpozij o bolestima jetre (Zadar)*, 1986:59. (in Croatian)
5. [Harmonizacija laboratorijskih nalaza u području opće medicinske biokemije]. *Hrvatska komora medicinskih biokemičara* 2004: 8. (in Croatian)
6. Rosalki SB, Foo AY. Lectin affinity electrophoresis of alkaline phosphatase for the differentiation of bone and hepatobiliary disease. *Electrophoresis*. 1989;10:604-11.
7. Dodig S, Richter D, Benko B, Živčić J, Raos M, Nogalo B, et al. Cut-off values of total serum IgE between nonatopic and atopic children in north-west Croatia. *Clin Chem Lab Med* 2006;44:639-47.
8. World Medical Association Declaration of Helsinki – Ethical Principles for Medical Research Involving Human Subjects, August 2005. Available at: <http://www.wma.net/e/policy/b3.htm>.
9. Oggero R, Mostert M, Spinello M, Iavarone A, Buffa J. Transient hyperphosphatasemia in infancy. Fifteen new cases. *Acta Paediatr Scand* 1988;77:257-9.
10. Stein P, Rosalki SB, Ying Foo A, Hjelm M. Transient hyperphosphatasemia of infancy and early childhood: clinical and biochemical features of 21 cases and literature review. *Clin Chem* 1987;33:313-8.
11. Eboriadou M, Skouli G, Panagopoulou P, Haidopoulou K, Makedou A, Verlamis G. Acute laryngotracheobronchitis and associated transient hyperphosphatasemia: a new case of transient hyperphosphatasemia in early childhood. *J Paediatr Child Health* 2006;42:149-50.
12. Suzuki M, Okazaki T, Nagai T, Toro K, Setonyi P. Viral infection of infants and children with benign transient hyperphosphatasemia. *FEMS Immunol Med Microbiol* 2002;12:215-8.
13. Arkan C, Arslan MT, Kilic M, Aydogdu S. Transient hyperphosphatasemia after pediatric liver transplantation. *Pediatr Int* 2006;48:390-2.
14. Parisi G, Chiarelli A, Brandani M, D'Onofrio A. Transient alkaline hyperphosphatasemia in childhood. A report of 4 clinical cases and etiopathogenetic hypotheses. *Minerva Pediatr* 1991;43:337-41.
15. Ranchin B, Villard F, Andre JL, Canterino I, Said MH, Boisson RC, et al. Transient hyperphosphatasemia after organ transplantation in children. *Pediatr Transplant* 2002;6:308-12.
16. Behúlová D, Bzdúch V, Holešová D, Vasilenková A, Ponec J. Transient hyperphosphatasemia of infancy and early childhood: study of 194 cases. *Clin Chem* 2000;46:1868-9.
17. Crofton PM. What is the cause of benign transient hyperphosphatasemia? A study of 35 cases. *Clin Chem* 1988;34:335-40.
18. Dodig S, Demirović J, Jelčić Ž, Richter D, Čepelak I, Raos M, et al. Alkaline phosphatase isoenzymes in children with respiratory disease. *Biochemia Medica* 2007;17:102-8.