

Naringenin reducira histopatološke promjene u jetri i bubregu miševa s dijabetesom

Sirovina, Damir; Oršolić, Nada; Zovko Končić, Marijana; Gregorović, Gordana

Source / Izvornik: **Arhiv za higijenu rada i toksikologiju, 2016, 67, 19 - 24**

Journal article, Published version

Rad u časopisu, Objavljena verzija rada (izdavačev PDF)

<https://doi.org/10.1515/aiht-2016-67-2708>

Permanent link / Trajna poveznica: <https://urn.nsk.hr/urn:nbn:hr:163:182999>

Rights / Prava: [In copyright](#)/[Zaštićeno autorskim pravom.](#)

Download date / Datum preuzimanja: **2024-07-28**



Repository / Repozitorij:

[Repository of Faculty of Pharmacy and Biochemistry University of Zagreb](#)



Naringenin ameliorates pathological changes in liver and kidney of diabetic mice: a preliminary study

Damir Sirovina¹, Nada Oršolić², Marijana Zovko Končić³, and Gordana Gregorović¹

Department of Biology, Division of Zoology, Faculty of Science¹, Department of Biology, Division of Animal Physiology, Faculty of Science², Faculty of Pharmacy and Biochemistry³, University of Zagreb, Zagreb, Croatia

[Received in August 2015; CrossChecked in August 2015; Accepted in February 2016]

The effect of naringenin, a flavonoid found in grapefruit, orange, and tomato, on lipid peroxidation and histopathological changes in the liver and kidneys of alloxan-induced diabetic mice were investigated. Two days after alloxan injection (75 mg kg⁻¹, *i.v.*), naringenin ethanolic solution (0.5 % v/v) was given to mice intraperitoneally (50 mg kg⁻¹ per day) for seven days. Naringenin's impact on lipid peroxidation was measured by the 2-thiobarbituric acid test and histopathological changes were examined under a light microscope. Naringenin administration resulted in a significant decrease of lipid peroxidation level in liver and kidney tissue, as well as in a decreased number of vacuolated liver cells and degree of vacuolisation. Indications of tissue repair in kidney suggested that amelioration of diabetes-induced renal damage could be achieved over a longer period of time. Findings suggest that naringenin could be considered a dietary supplement in the prevention or treatment of diabetic complications and other diseases connected with oxidative stress, and gives a hope that it could show similar effects in the treatment of diabetes in humans.

KEY WORDS: *diabetes; diabetic kidney; histopathology; lipid peroxidation; liver disease; naringenin*

Naringenin (2,3-dihydro-5,7-dihydroxy-2-(4-hydroxyphenyl)-4H-1-benzopyran-4-one) is a flavonoid, a flavanone, mostly found in grapefruits, oranges and cooked tomato paste (1). It has been reported to show low toxicity and is therefore suitable as a dietary supplement (2). Naringenin has antioxidant, immunomodulatory, and anti-inflammatory effect on the human body. It has been proven effective in the regulation of a variety of disorders related to diabetes and its complications (3, 4). Naringenin participates in the regulation of many metabolic and signaling pathways, like the regulation of liver apolipoprotein B, an indicator of atherosclerosis (3, 5, 6). Furthermore, Heo et al. (7) confirmed its neuroprotective effect by reducing the oxidative stress induced by amyloid beta-protein-induced reactive oxygen species (ROS). Flavonoids may realise their protective role through several mechanisms like by activating and protecting intercellular antioxidant enzymes (8), or by directly or indirectly reacting with ROS through hydrogen atom transfer, single electron transfer or metal chelation (9). The antioxidant activity of flavonoids and their metabolites depends on their structural features, primarily the existence of functional hydroxyl groups in the B chain. An active 4' hydroxyl group in the B ring of naringenin is found to be responsible for its antioxidant activity (2). Bioavailability of naringenin depends on its

source and form (1, 2, 10). It is possible to buy naringenin as a pure supplement but in natural products naringenin mainly occurs as naringenin-7-rhamnoglucoside or naringenin-7-glucoside. It has been reported that bioavailability of naringenin and naringenin-7-glucoside are similar, whereas naringenin-7-rhamnoglucoside exhibits slower absorption (2, 10).

Diabetes mellitus is a progressive and possibly the world's fastest growing metabolic disorder which includes hyperglycaemia and oxidative stress as both a cause and a consequence (8, 11). Hyperglycaemia generates ROS that cause oxidative damage to the whole body, particularly to the cardiovascular and immunological systems, nerves, liver, and kidneys (12). It also attenuates anti-oxidative mechanisms through nonenzymatic glycosylation of anti-oxidant enzymes (8). The products of lipid peroxidation, lipid radicals and lipid peroxides, are associated with damage to the liver, kidneys, brain, blood vessels, and other organs and tissues (13).

In this study, we examined the effect of naringenin on lipid peroxidation and histopathological changes of the liver and kidneys caused by alloxan-induced diabetes in mice because the liver and kidneys are among the organs most sensitive to oxidative stress in diabetes. The goal of our research was to find out more about the action of naringenin on the body affected by diabetes so it could be better evaluated as a potential therapeutic agent.

Correspondence to: Damir Sirovina, Department of Biology, Faculty of Science, University of Zagreb, HR-10 000 Zagreb, Rooseveltov trg 6, Croatia; Tel: +385 1 4877 747, Fax: +385 1 4826260, E-mail: sirovina@biol.pmf.hr

MATERIALS AND METHODS

Animals

Swiss albino inbred mice, male and female, 60 to 70 days old, weighing 20 to 25 g, were obtained from the Department of Animal Physiology, Faculty of Science, University of Zagreb. They were fed a standard laboratory diet (4 RF 21, Mucedola, Settimo Milanese, Italy), tap water was given *ad libitum* and they were kept in individual cages at 12 h light: 12 h dark cycle. The animals were treated in compliance with the guidelines in force in the Republic of Croatia (Law on the Welfare of Animals, N.N. #19, 1999) and with the Guide for the Care and Use of Laboratory Animals, DHHS Publ. # (NIH) 86-123. The Ethical Committee of the Faculty of Science, University of Zagreb, Croatia, approved the study.

Chemicals and apparatus

Naringenin and Tween-40 (polyoxyethylene sorbitan monopalmitate) were purchased from Sigma-Aldrich Chemical Co. (USA). Prior to use, naringenin was dissolved in saline solution with 0.5 % v/v ethanol. Perkin Elmer Lambda 25 spectrophotometer (Perkin Elmer, USA) was used for absorbance measurements. Photomicrographs were taken by a digital camera (Nikon DMX1200) and Imaging Software Lucia G 4.80 (Laboratory Imaging Ltd., Prague, Czech Republic).

Experimental design

Thirty-nine mice were randomly divided into three groups, as follows:

Group (i): nondiabetic animals who received 0.5 mL of saline solution with 0.5 % v/v ethanol per day by intraperitoneal (*i.p.*) injection for seven days;

Group (ii): diabetic animals who were administered alloxan intravenously (*i.v.*) in a single dose of 75 mg kg⁻¹ body weight; these served as the untreated diabetic group. They received 0.5 mL of saline solution with 0.5 % v/v ethanol per day by *i.p.* injection for seven days;

Group (iii): naringenin group; diabetic animals (alloxan-induced) who received a naringenin solution *i.p.* in a daily dose of 50 mg kg⁻¹ for seven days, beginning two days after the alloxan injection; these served as the naringenin-treated diabetic group.

Five mice from each group were used for the experiments.

Induction of experimental diabetes and determination of serum glucose levels

The induction of diabetes by a single intravenous injection of freshly prepared saline solution of alloxan monohydrate (75 mg kg⁻¹, *i.v.*) and the selection of animals

for the study were carried out as described in our previous research (14).

Tissue harvesting

Five mice from each group were sacrificed by cervical dislocation on the ninth day after the alloxan injection. Subsequently the whole liver and kidneys were harvested for the determination of lipid peroxidation and histopathological analysis.

Determination of lipid peroxidation

Samples of liver and kidney tissue were prepared as described in our previous research (9). Lipid peroxidation was determined as described by Nabavi et al. (15). For the construction of calibration curve, tetramethoxypropane was used. The levels of lipid peroxides were expressed as nmoles of malondialdehyde (MDA) formed per mg⁻¹ protein. Protein concentration was determined as described by Navarro et al. (16). Crystalline bovine serum albumin was used for calibration curve.

Histopathological analysis

Histopathological analysis was conducted as described in our previous research (14). Liver tissue sections were examined for lymphocyte infiltrations and vacuolisation. Kidney sections were examined for lymphocyte infiltrations, changes in renal corpuscles, and renal tubules.

Statistical analyses

The results are representative of three independent experiments and were expressed as mean ± SD. Statistical comparisons were made using Student's *t*-test. For statistical analyses we used GraphPad Prism version 5.01 for Windows, GraphPad Software, San Diego California USA, www.graphpad.com. The level of statistical significance was set at $p < 0.05$.

RESULTS AND DISCUSSION

Naringenin, a naturally occurring flavonoid found in citrus fruits, is known to have anticarcinogenic, antidiabetic, antiosteoporetic, and anti-atherosclerotic properties (2, 17, 18). Many studies have shown positive effects of plant extracts (18), but it is also necessary to know what effects a particular component of the extract has. Furthermore, we must consider possible toxic effects from plant extracts (19). We therefore decided to use pure naringenin. Different studies use different doses and different ways of drug application, like peroral and intraperitoneal. We decided to administer naringenin to mice intraperitoneally (50 mg kg⁻¹ per day) because this type of application and this dose are frequently used and they have proven to be non-toxic. Furthermore, some studies show that naringenin taken perorally and intraperitoneally shows similar activity (20)

and a dose of 50 mg kg⁻¹ for a mouse corresponds to a dose of 4 mg for a human. For an average person that would be about 250 mg of naringenin, which can be found in about half a liter of grapefruit juice (20-22). Our previous results (4) demonstrated that diabetic mice treated with naringenin survived a period of 50 days and after a critical period of three to seven days their appearance and behaviour did not differ from those of the healthy mice; suggesting a protective effect of naringenin on the organism. Furthermore, comet assay showed that naringenin reduced the level of DNA damage in lymphocytes but did not affect the level of DNA damage in the liver and kidneys. Since oxidative stress plays a pivotal role in the development of complications in diabetes, and positive effects of naringenin in the control of diabetes and other oxidative stress related diseases have been proven, we have explored the effect of naringenin on lipid peroxidation and histopathological changes of the liver and kidneys caused by alloxan-induced diabetes in mice.

Lipid peroxidation in the liver and kidney tissue was significantly reduced in animals treated by naringenin compared to the untreated diabetic animals (Figure 1). Similarly, Cavia-Saiz et al. (23) showed that naringenin was able to inhibit lipid peroxidation in rat liver tissue induced by potent oxidants, hydroxyl radical and peroxy radical. In carbon tetrachloride-induced nephrotoxicity,

naringenin has also shown the ability for nephroprotection, as demonstrated by several assays, including the measurement of MDA in kidney tissue (24). The antioxidant activity of flavonoids and their metabolites depends on their structural features, like the arrangement of functional hydroxyl groups, O-methylation, differences in the main nuclear structure, such as the presence or absence of an unsaturated 2-3 bond and/or a 4-carbonyl group, degree of polymerisation and other (25). Naringenin's antioxidant/antiradical ability is based on its single 4' hydroxyl group in the B ring of the molecule (2). However, structural features may not completely reflect the behaviour of naringenin in an organism. For example, it has been found that the antiradical activity of naringenin depends on the polarity of the solvent because hydrogen bonding interactions are a crucial factor which influences the reaction rate of this flavonoid and its antioxidant properties (26).

Furthermore, our results show that naringenin reduces histopathological changes in the liver and kidneys. Similarly to Khalil et al. (27), our histological analysis of liver tissue in the control mice with alloxan-induced diabetes shows more or less vacuolated liver cells (Figure 2a,2b), a probable consequence of fat metabolism disorders. In half of the samples, the liver cells are more vacuolated around the central veins than around Kiernan's spaces (Figure 2a). Besides vacuolated cells, lymphocyte infiltrations were also observed, suggesting inflammatory processes. In the second half of the samples, almost all cells were considerably vacuolated in the central and peripheral part of individual lobules (Figure 2b). In these samples, lymphocyte infiltrations were not found. In comparison with the untreated diabetic mice, the livers of the diabetic mice treated with naringenin showed a smaller amount of vacuolated cells with a lower degree of vacuolisation (Figure 2c, 2d), which confirms the beneficial effect of naringenin. A few small lymphocyte infiltrations were found in all the samples. Infiltrations were present in the parenchyma and next to the blood vessels in some Kiernan's spaces (Figure 2d).

In the kidneys of the control diabetic mice, changes were found in the renal corpuscles and tubules. Bowman's spaces of most renal corpuscles of the diabetic control mice were very narrow or completely reduced (Figure 3a, 3b, 3c), which was probably a consequence of the proliferation of mesangial and/or endothelial cells of the glomerulus. These results are in accordance with the results described by Prabhakar et al. (28) and Teoh et al. (29). In some corpuscles, the parietal layer of Bowman's capsule, usually made of low squamous epithelium, was much thicker and composed of cubic cells (Figure 3b). Fioretto and Mauer (30) confirmed that mesangial expansion is the key structural transformation that leads to disturbances in the functioning of renal corpuscles in diabetes. However, Wolf et al. (31) showed that, besides

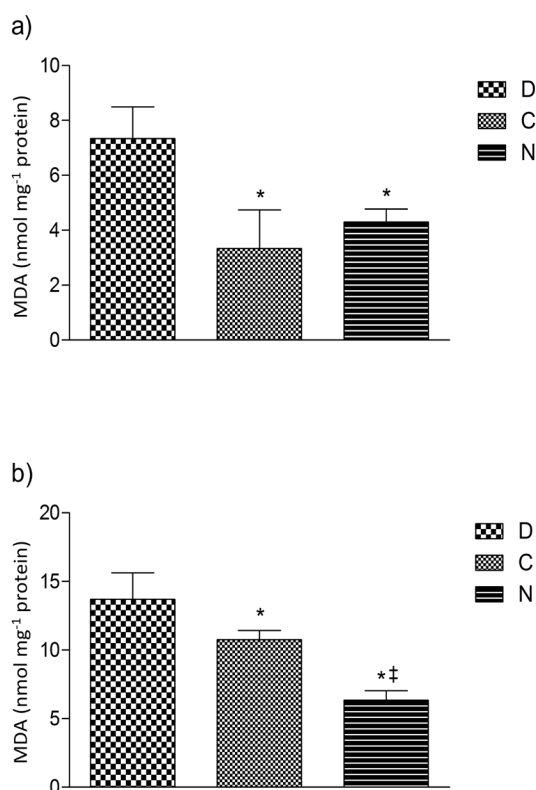


Figure 1 Levels of lipid peroxidation in **a)** liver and **b)** kidney of healthy (C), untreated diabetic mice (D) and diabetic mice treated with naringenin (N). Values are means \pm SD ($n = 4$). (* statistical difference with untreated diabetic mice; ‡ statistical difference with healthy mice; Student's *t*-test, $p < 0.05$)

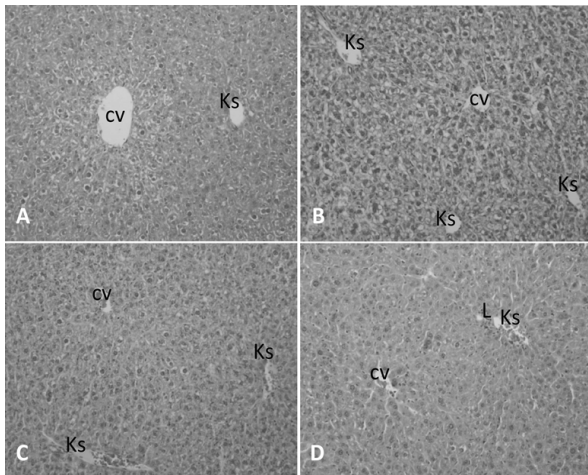


Figure 2 Liver tissue of diabetic mice stained with HE (200×) (a-b) Control mice treated with ethanolic solution. (a) In part of the samples, the liver cells around the central veins (cv) are more vacuolated than the cells around Kiernan's spaces (Ks). (b) The degree and distribution of vacuolated cells in the centre and periphery of lobules are equal in the second part of the samples. Most of the cells are considerably vacuolated. (c-d) Diabetic mice treated with ethanolic solution of naringenin have considerably less vacuolated cells compared to diabetic control. (c) In one part of the samples, there are fewer vacuolated cells in the area around the central vein (cv), and in the other part of the samples vacuolated cells are equally distributed throughout the lobules (d).
cv- central vein; Ks-Kiernan's space; L-lymphocyte infiltration near vein in Kiernan's space

mesangial expansion, the changes of the visceral layer of Bowman's capsule can also affect the filtration barrier. Our analysis showed the thickening of the parietal layer of Bowman's capsule (Figure 3b) and such changes may contribute to the reduction of Bowman's space.

The tubule epithelium was damaged to varying degrees from one sample to the other. Tubules with cytoplasmic vacuolisation, intraluminal vacuoles, as well as with thinned epithelium with or without intraluminal eosinophilic mass were found (Figure 3a, 3c). The epithelium of some proximal tubules showed eosinophilic cytoplasm and reduced nucleus, i.e. the signs of necrosis (Figure 3a, 3b). Similar to our findings, Prabhakar et al. (28) described enlarged tubules and atrophy, and Teoh et al. (29) necrosis of proximal tubules. The vacuolated cells of proximal tubules and Henle's loop were described in our previous study (14). A few small lymphocyte infiltrations were found in the interstitium in all of the samples. Tubular changes indicate disturbances in their function.

When we compared the kidney histology of the diabetic mice treated with naringenin to the untreated diabetic mice, no significant structural changes were observed, although in some mice more or less basophilic tubules indicated attempts to regenerate damaged epithelium (Figure 3d). Differences in the impact of naringenin on the liver and kidney tissue could be due to the effect of the first pass through the liver, where some ingredients with antioxidant properties undergo biotransformation. This may prevent or

prolong the possible beneficial effects in other tissues. Furthermore, the liver is rich in antioxidant enzymes whose activities can be elevated by polyphenols (32) and can protect the liver and/or allow fast repair of damage. Although we did not find significant positive changes in the kidneys of the diabetic mice treated with naringenin for seven days, indications of tissue repair (Figure 3d) suggest that a better improvement of renal damage could be achieved over a longer period of time. This suggestion is supported by the study conducted by Renugadevi and Milton Prabu (33), which showed that the co-administration of naringenin and Cd for 28 days markedly reduced lipid peroxidation and preserved the normal histology of the renal tissue of diabetic rats. In addition, this suggestion is supported by the results of our previous study (34) where in a short period of time propolis failed to significantly affect the pathological changes in the kidneys, as well as the results of a study conducted by El Agawany et al. (35) where longer propolis administration showed significantly better results.

Taking into account our results and reports from other researchers, the findings suggest that naringenin has a positive effect on the liver and kidneys, two organs most sensitive to oxidative stress and disorders of fat metabolism in diabetes. This study implies that naringenin and its natural sources, such as grapefruit juice, could be considered a dietary supplement in the prevention or treatment of diabetic

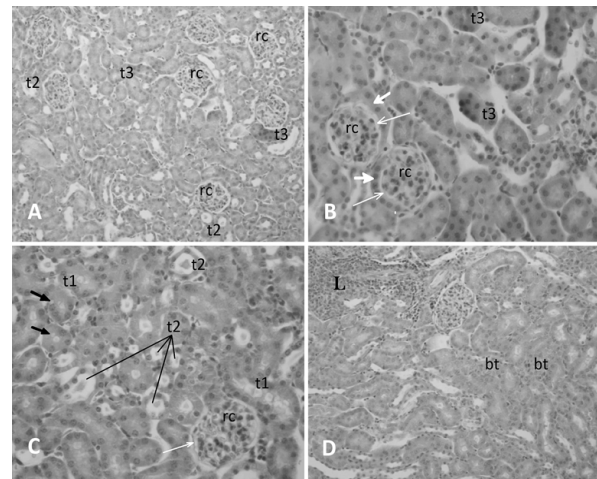


Figure 3 Kidney tissue of diabetic mice stained with HE (200×, 400×)

(a-c) Control diabetic mice treated with ethanolic solution (a 200×; b, c 400×). Intercapsular areas of most renal corpuscles (rc) are narrow (thin white arrows), and the outer layers of Bowman's capsule thickened (thick white arrows). Renal tubules with vacuolated cytoplasm (thick black arrows), tubules with intraluminal vacuoles (t1), tubules with thinned epithelium (t2) with or without intraluminal smaller or larger eosinophilic masses, and eosinophilic tubules (t3) are signs of damage of the tubules epithelium.

(d) Diabetic mice treated with ethanolic solution of naringenin (200×). In the renal cortex, larger lymphocyte infiltrations (L) were found and slightly more tubules with thinned epithelium compared to diabetic control. Some basophilic tubules (bt) were also found

complications and other diseases connected with oxidative stress. However, further research is needed to address all the possible effects of naringenin in the regulation of metabolic and signaling pathways involved in oxidative stress in diabetes.

Acknowledgements

This work was supported by the Ministry of Science, Education, and Sports of the Republic of Croatia project No. 119-0000000-1255.

Conflict of Interest Statement

The authors declare that there is no conflict of interest.

REFERENCES

1. Bugianesi R, Catasta G, Spigno P, D'Uva A, Maiani G. Naringenin from cooked tomato paste is bioavailable in men. *J Nutr* 2002;132:3349-52. PMID: 12421849
2. Orhan IE, Nabavi SF, Daglia M, Tenore GC, Mansouri K, Nabavi SM. Naringenin and Atherosclerosis: A Review of Literature. *Curr Pharm Biotechnol* 2015;16:245-51. doi: 10.2174/1389201015666141202110216
3. Mulvihill EE, Allister EM, Sutherland BG, Telford DE, Sawyez CG, Edwards JY, Markle JM, Hegele RA, Huff MW. Naringenin prevents dyslipidemia, apolipoprotein B overproduction, and hyperinsulinemia in LDL receptor-null mice with diet-induced insulin resistance. *Diabetes* 2009;58:2198-210. doi: 10.2337/db09-0634
4. Oršolić N, Gajski G, Garaj-Vrhovac V, Đikić D, Prskalo ZŠ, Sirovina D. DNA-protective effects of quercetin or naringenin in alloxan-induced diabetic mice. *Eur J Pharmacol* 2011;656:110-8. doi: 10.1016/j.ejphar.2011.01.021
5. Mulvihill EE, Assini JM, Sutherland BG, DiMattia AS, Khami M, Koppes JB, Sawyez CG, Whitman SC, Huff MW. Naringenin decreases progression of atherosclerosis by improving dyslipidemia in high-fat-fed low-density lipoprotein receptor-null mice. *Arterioscler Thromb Vasc Biol* 2010;30:742-8. doi: 10.1161/ATVBAHA.109.201095
6. Allister EM, Borradaile NM, Edwards JY, Huff MW. Inhibition of microsomal triglyceride transfer protein expression and apolipoprotein B100 secretion by the citrus flavonoid naringenin and by insulin involves activation of the mitogen-activated protein kinase pathway in hepatocytes. *Diabetes* 2005;54:1676-83. doi: 10.2337/diabetes.54.6.1676
7. Heo HJ, Choi SJ, Kim HK, Shin DH. Effect of antioxidant flavanone, naringenin, from *Citrus junos* on neuroprotection. *J Agric Food Chem* 2004;52:1520-5. doi: 10.1021/jf035079g
8. Oršolić N, Bašić I. Honey bee products and their polyphenolic compounds in treatment of diabetes. In: Govil JN, Singh VK, editors. *Recent Progress in Medical Plants Volume 22: Phytopharmacology and Therapeutic Values IV*. Houston (TX): Studium Press, LLC; 2008. p. 455-71.
9. Leopoldini M, Russo N, Toscano M. The molecular basis of working mechanism of natural polyphenolic antioxidants. *Food Chem* 2011;125:288-306. doi: 10.1016/j.foodchem.2010.08.012
10. Felgines C, Texier O, Morand C, Manach C, Scalbert A, Régerat F, Rémésy C. Bioavailability of the flavanone naringenin and its glycosides in rats. *Am J Physiol Gastrointest Liver Physiol* 2000;279:G1148-54. PMID:11093936
11. Yue KK, Chung WS, Leung AW, Cheng C. Redox changes precede the occurrence of oxidative stress in eyes and aorta, but not in kidneys of diabetic rats. *Life Sci* 2003;73:2557-70. doi: 10.1016/S0024-3205(03)00662-3
12. Obrosova IG, Minchenko AG, Vasupuram R, White L, Abatan OI, Kumagai AK, Frank RN, Stevens MJ. Aldose reductase inhibitor fidarestat prevents retinal oxidative stress and vascular endothelial growth factor overexpression in streptozotocin-diabetic rats. *Diabetes* 2003;52:864-71. doi: 10.2337/diabetes.52.3.864
13. Yue KK, Leung SN, Man PM, Yeung WF, Chung WS, Lee KW, Leung AW, Cheng CH. Alterations in antioxidant enzyme activities in the eyes, aorta and kidneys of diabetic rats relevant to the onset of oxidative stress. *Life Sci* 2005;77:721-34. doi: 10.1016/j.lfs.2004.10.081
14. Sirovina D, Oršolić N, Zovko Končić M, Kovačević G, Benković V, Gregorović G. Quercetin vs chrysin: effect on liver histopathology in diabetic mice. *Hum Exp Toxicol* 2013;32:1058-66. doi: 10.1177/0960327112472993
15. Nabavi SM, Nabavi SF, Eslami S, Moghaddam AH. *In vivo* protective effects of quercetin against sodium fluoride-induced oxidative stress in the hepatic tissue. *Food Chem* 2012;132:931-5. doi: 10.1016/j.foodchem.2011.11.070
16. Navarro SA, Serafim GG, Mizokami SS, Hohmann MSN, Casagrande R, Verri Jr WA. Analgesic activity of piracetam: Effect on cytokine production and oxidative stress. *Pharmacol Biochem Behav* 2013;105:183-92. doi: 10.1016/j.pbb.2013.02.018
17. Oršolić N, Goluža E, Đikić D, Lisičić D, Sašilo K, Rodak E, Jeleč Ž, Vihnanek Lazarus M, Orct T. Role of flavonoids on oxidative stress and mineral contents in the retinoic acid-induced bone loss model of rat. *Eur J Nutr* 2014;53:1217-27. doi: 10.1007/s00394-013-0622-7
18. Khalili M, Ebrahimzadeh MA, Safdari Y. Antihemolytic activity of thirty herbal extracts in mouse red blood cells. *Arh Hig Rada Toksikol* 2014;65:399-406. doi: 10.2478/10004-1254-65-2014-2513
19. Cvjetko P, Zovko M, Balen B. Proteomics of heavy metal toxicity in plants. *Arh Hig Rada Toksikol* 2014;65:1-18. doi: 10.2478/10004-1254-65-2014-2443
20. Kanno S, Tomizawa A, Hiura T, Osanai Y, Shouji A, Ujibe M, Ohtake T, Kimura K, Ishikawa M. Inhibitory effects of naringenin on tumor growth in human cancer cell lines and sarcoma S-180-implanted mice. *Biol Pharm Bull* 2005;28:527-30. doi: 10.1248/bpb.28.527
21. Erlund I, Meririnne E, Alftan G, Aro A. Plasma kinetics and urinary excretion of the flavanones naringenin and hesperetin in humans after ingestion of orange juice and grapefruit juice. *J Nutr* 2001;131:235-41. PMID:11160539
22. Reagan-Shaw S, Nihal M, Ahmad N. Dose translation from animal to human studies revisited. *FASEB J* 2008;22:659-61. doi: 10.1096/fj.07-9574LSF
23. Cavia-Saiz M, Busto MD, Pilar-Izquierdo MC, Ortega N, Perez-Mateos M, Muniz P. Antioxidant properties, radical scavenging activity and biomolecule protection capacity of flavonoid naringenin and its glycoside naringin: a comparative study. *J Sci Food Agric* 2010;90:1238-44. doi: 10.1002/jsfa.3959

24. Hermenean A, Ardelean A, Stan M, Herman H, Mihali CV, Costache M, Dinischiotu A. Protective effects of naringenin on carbon tetrachloride-induced acute nephrotoxicity in mouse kidney. *Chem-Biol Interact* 2013;205:138-47. doi: 10.1016/j.cbi.2013.06.016
25. Heim KE, Tagliaferro AR, Bobilya DJ. Flavonoid antioxidants: chemistry, metabolism and structure-activity relationships. *J Nutr Biochem* 2002;13:572-84. doi: 10.1016/S0955-2863(02)00208-5
26. Jabbari M, Mir H, Kanaani A, Ajloo D. Kinetic solvent effects on the reaction between flavonoid naringenin and 2,2-diphenyl-1-picrylhydrazyl radical in different aqueous solutions of ethanol: An experimental and theoretical study. *J Mol Liq* 2014;196:381-91. doi: 10.1016/j.molliq.2014.04.015
27. Khalil M, Mohamed G, Dallak M, Al-Hashem F, Sakr H, Eid RA, Adly MA, Al-Khateeb M, Banihani S, Hassan Z, Bashir N. The effect of *Citrullus colocynthis* pulp extract on the liver of diabetic rats a light and scanning electron microscopic study. *Am J Biochem Biotechnol* 2010;6:155-63. doi: 10.3844/ajbbsp.2010.155.163
28. Prabhakar S, Starnes J, Shi S, Lonis B, Tran R. Diabetic nephropathy is associated with oxidative stress and decreased renal nitric oxide production. *J Am Soc Nephrol* 2007;8:2945-52. doi: 10.1681/ASN.2006080895
29. Teoh SL, Latiff AA, Das S. Histological changes in the kidneys of experimental diabetic rats fed with *Momordica charantia* (bitter melon) extract. *Rom J Morphol Embryol* 2010;51:91-5. PMID: 20191126
30. Fioretto P, Mauer M. Histopathology of diabetic nephropathy. *Semin Nephrol* 2007;27:195-207. doi: 10.1016/j.semnephrol.2007.01.012
31. Wolf G, Chen SD, Ziyadeh FN. From the periphery of the glomerular capillary wall toward the center of disease - Podocyte injury comes of age in diabetic nephropathy. *Diabetes* 2005;54:1626-34. doi: 10.2337/diabetes.54.6.1626
32. Martín MÁ, Serrano AB, Ramos S, Pulido MI, Bravo L, Goya L. Cocoa flavonoids up-regulate antioxidant enzyme activity via the ERK1/2 pathway to protect against oxidative stress-induced apoptosis in HepG2 cells. *J Nutr Biochem* 2010;21:196-205. doi: 10.1016/j.jnutbio.2008.10.009
33. Renugadevi J, Milton Prabu S. Naringenin protects against cadmium-induced oxidative renal dysfunction in rats. *Toxicology* 2009;256:128-34. doi: 10.1016/j.tox.2008.11.012
34. Oršolić N, Sirovina D, Zovko Končić M, Lacković G, Gregorović G. Effect of Croatian propolis on diabetic nephropathy and liver toxicity in mice. *BMC Complement Altern M* 2012;12:117. doi: 10.1186/1472-6882-12-117
35. El Agawany A, Meguid EMA, Khalifa H, El Harry M. Propolis effect on rodent models of streptozotocin-induced diabetic nephropathy. *J Am Sci* 2012;8:1125-32.

Naringenin reducira histopatološke promjene u jetri i bubregu miševa s dijabetesom

Istražen je učinak naringenina, flavonoida dostupnoga iz grejpa, naranče i rajčice, na razinu lipidne peroksidacije te patohistološke promjene u jetri i bubregu miševa s dijabetesom prouzročeni aloksanom. Dva dana nakon injekcije aloksana (75 mg kg⁻¹, iv) započeta je terapija etanolnom otopinom naringenina (0.5% v / v). Naringenin je injiciran miševima intraperitonealno u dozi od 50 mg kg⁻¹ tijekom sedam dana. Učinak naringenina na razinu lipidne peroksidacije određen je metodom s tiobarbiturnom kiselinom, a histopatološke promjene jetre i bubrega utvrđene su svjetlosnim mikroskopom. Terapija naringeninom prouzročila je značajno smanjenje ne samo razine lipidne peroksidacije u tkivu jetre i bubrega nego i broja vakuoliziranih stanica jetre te stupnja njihove vakuolizacije. Naznake oporavka tkiva u bubregu navode na zaključak da bi dugotrajna terapija mogla smanjiti oštećenja bubrega prouzročena dijabetesom. Zaštitni učinak naringenina u razvoju dijabetičkih komplikacija u miševa daje nadu da je sličan, pozitivan učinak moguć i u ljudi.

KLJUČNE RIJEČI: dijabetes; dijabetička nefropatija; histopatologija; lipidna peroksidacija; naringenin; oštećenja jetre